

Solución del caso: Endoscopic diagnosis of esophageal subepithelial lesion.

The diagnostic role of endoscopic ultrasonography and Fuji intelligent chromo endoscopy

Viene de la página 5

A substantial embossment of the lesion and a marked vascular net in the proximity is observed with Fuji Intelligent Chromo Endoscopy (FICE), (Figure 2). These findings reinforce the belief of the vascular origin of the process. EUS (Figure 3 and 4) showed an hypoechoic lesion originating in the deeper mucosal layer that exhibited doppler signs insi-

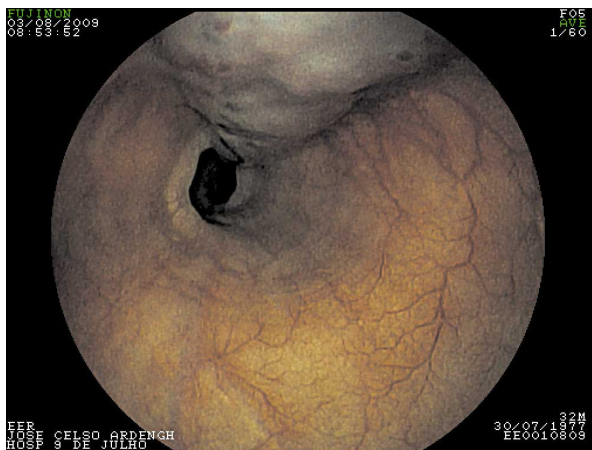


Figure 2. Endoscopic aspect of the lesion with FICE: embossment of the lesion and vascular net around it.

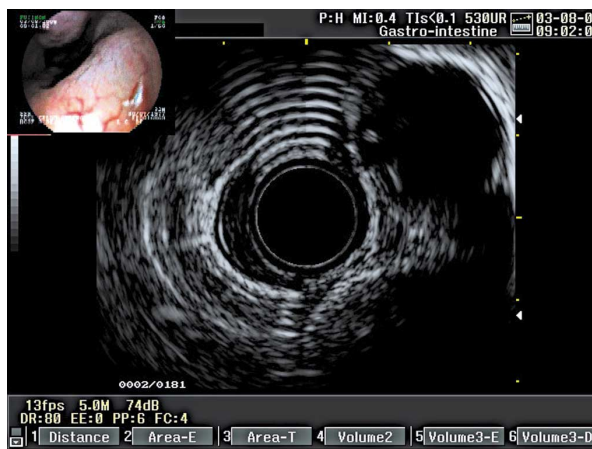


Figure 3. EUS aspect of the lesion: hypoechoic lesion originating in the deeper mucosal layer and sparing the submucosal and muscular layers.

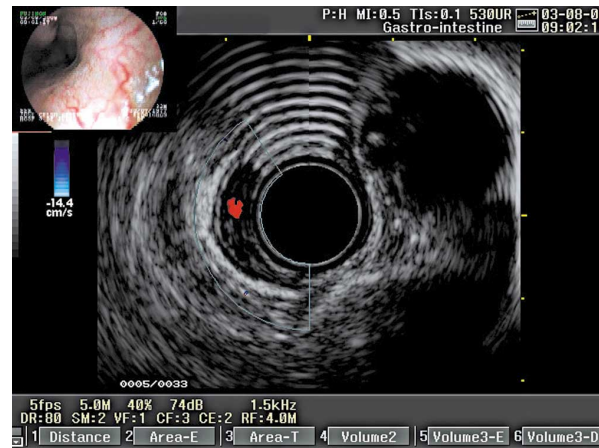


Figure 4. EUS aspect of the lesion: doppler sign inside it.

de and spared the submucosal and muscular layers. These findings are consistent with those described for esophageal haemangioma.^{2,8}

The esophageal haemangioma is a rare entity, representing less than 3% of the benign tumors of the esophagus.¹ When they involve the gastrointestinal tract, the most frequent sites are the small bowel, the colon and the stomach.² The inferior portion is the site of the esophagus most frequently affected.³ When patients present with symptoms, dysphagia, bleeding, epigastric pain, thoracic pain and melena are the most common complaints.² Hemangiomas are classified as cavernous, capillary and mixed types.⁴ The cavernous type is composed of large dilated vascular spaces filled with blood and the capillary type is composed of conglomerates of small, thin-walled vessels. The cavernous type, when large, may bleed seriously, with platelet consumption within the lesion being an aggravating factor. The bleeding is often episodic and initiates in childhood.⁵ The endoscopic feature is very suggestive and the biopsy may be avoided due the risk of hemorrhage.⁵ Atypical cases may be confounded with esophageal carcinoma.¹

The treatment of choice for esophageal haemangioma has classically been described as surgical, but with the recent advances in therapeutic endoscopy, many reports have appeared in medical literature for the endoscopic treatment of esophageal haemangiomas, such as endoscopic band ligation, snare polypectomy, mucosectomy, sclerotherapy and laser fulguration.^{2,6-8}

In the present report we describe a case of a young symptomless man with an incidental discovered esophageal lesion. We believe that we added important data to the diagnosis of esophageal haemangioma by means of little invasive procedures such as EUS and FICE. The endoscopic ultrasonography findings were consistent with those described in other publications for this pathology. We did not find previous reports in the literature using FICE for the diagnosis of gastrointestinal tract haemangiomas. It is our opinion that FICE reinforced the diagnosis of hemangioma in our case by enhancing the vascular structure and nature of the lesion. However, these results should be supported by more robust data.

On the other hand, we do not have notice about the natural history of esophageal hemangiomas in symptomless young patients. To our knowledge there are no papers comparing the morbidity and mortality between the natural history and the surgery. Therefore, in the absence of a more reliable report and after a meticulous explanation, the pa-

tient preferred an expectant behavior with follow-up of the lesion.

Referencias

1. Chella B, Nosotti M, Baisi A, Lattuada A, Mazzone A, Santambrogio L. Unusual presentation of a transperietal cavernous hemangioma of the esophagus. *Dis Esophagus* 2005;18:349-354.
2. Nagata-Narumiya T, Nagai Y, Kashiwagi H, Hama M, Takifuji K, Tanimura H. Endoscopic sclerotherapy for esophageal hemangioma. *Gastrointest Endosc* 2000;52:285-287.
3. Govoni AF. Hemangiomas of the esophagus. *Gastrointest Radiol* 1982;7:113-117.
4. Elsayes KM, Menias CO, Dillman JR, Platt JF, Willatt JM, Hieken JP. Vascular malformation and hemangiomatosis syndromes: spectrum of imaging manifestations. *AJR Am J Roentgenol* 2008;190:1291-1299.
5. Regula J, Wronska E, Pachlewski J. Vascular lesions of the gastrointestinal tract. *Best Pract Res Clin Gastroenterol* 2008;22:313-328.
6. Shigemitsu K, Naomoto Y, Yamatsuji T, Ono K, Aoki H, Haisa M, Tanaka N. Esophageal hemangioma successfully treated by fulguration using potassium titanyl phosphate/yttrium aluminium garnet (KTP/YAG) laser: a case report. *Dis Esophagus* 2000;13:161-164.
7. Liu J, Wang HH, Gao W, Chi Y, Tian Y. Cervical esophageal capillary hemangioma removed by combined and sequential endoscopic ligation and snare polypectomy. *Endoscopy* 2008;40 (Suppl 2):E179-E180.
8. Elmunzer BJ, Piraka C. Symptomatic esophageal hemangioma removed by EMR. *Gastrointest Endosc* 2008;67:173-174.