

◆ IMAGEN DEL NÚMERO

Invitamos a los lectores de Acta a que envíen casos con interés clínico o diagnóstico para su publicación en esta sección.

Endoscopic diagnosis of esophageal subepithelial lesion

José Júlio Ribeiro Viana,³ José Celso Ardengh,¹ Artur Adolfo Parada,¹ Matheus Degiovanni,¹ Nelson Heitor Vieira Coelho,⁴ Fábio Kennedy Almeida Trigueiro²

¹ Unidade de endoscopia digestiva do Hospital Nove de Julho, São Paulo, Brasil.

² Serviço de endoscopia digestiva de Campina Grande, Paraíba, Brasil.

³ Setor de endoscopia digestiva do Hospital de Câncer, Pernambuco, Brasil.

⁴ Setor de endoscopia digestiva – Hospital Mãe de Deus e Moinhos de Vento, RS, Brasil.

We report the case of a 32-year-old man who was seen in another medical service with complaint of epigastric pain without alarm symptoms. Otherwise, the medical history and physical examination were normal. An endoscopic examination of the esophagus, stomach and duodenum revealed a low grade erosive gastritis and the scar of a previous duodenal ulcer. A rapid urease test for *Helicobacter pylori* was positive. As an incidental finding in the endoscopic examination an elevated lesion was described, located in mid esophagus, with signs suggesting a subepithelial tumor. The patient was

referred to our endoscopic unit with the purpose of elucidating the diagnosis by means of an endoscopic ultrasonography examination (EUS).

Previously to EUS, we performed a second endoscopic examination of the upper gastrointestinal organs that revealed a protrusive lesion in the mid-esophagus, harboring a third of the esophageal luminal circumference, measuring 4 cm in the longitudinal axis, looking soft and depressible when touched with the biopsy forceps, and presenting with a blue color and soft surface although with some red spots (Figure 1).

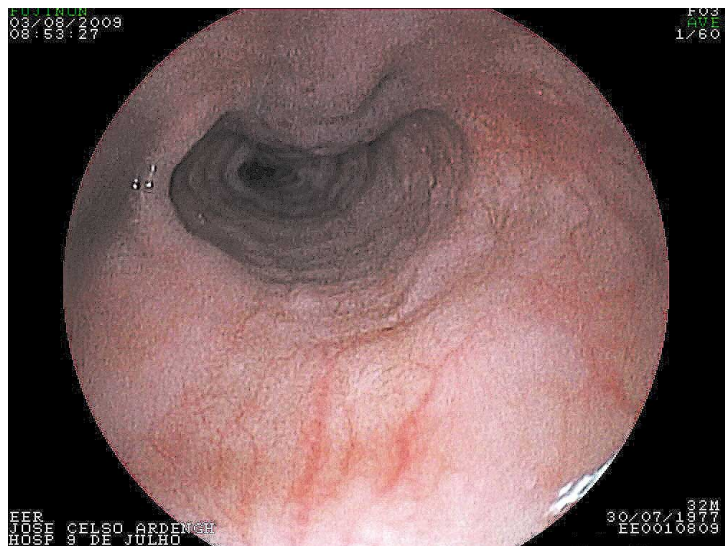


Figure 1. Endoscopic aspect of the lesion.

Correspondencia: José Celso Ardengh
Serviço de Endoscopia Digestiva, Hospital Nove de Julho.
Rua Peixoto Gomide, 613 – São Paulo, Brasil. 0149001.
Tel: (021)11 32898993 and 32510015
E-mail: jcelso@uol.com.br

What is the diagnosis?

Resolución del caso en la página 83