Solución del caso: Intra-abdominal recurrent abscess following sleeve gastrectomy

Viene de la página 185

A percutaneous placement of a pigtail catheter was required and a gastrocolic fistula was suspected.

Gastrocolic fistulas are uncommon. They have been historically observed as a complication of gastric or colon cancer, but also occur as a complication of benign conditions.[1-4]

An esophageal stent was positioned from the inferior third segment of the esophagus into the gastric pouch by upper endoscopy and under fluoroscopic guidance. An upper gastrointestinal series performed in the first postoperative day showed no evidence of leak from the fistula (Figure 3). The patient was discharged home on 7th postoperative day after resumption of normal oral intake. Seven weeks later, the stent was retrieved by endoscopy. The patient eventually required laparoscopic surgery to resolve a recurrent gastocolic fistula. The safety and feasibility of stent implantation for treatment of gastrocolic fistula are discussed.

There are several reports of small case series or animal studies using endoluminal procedures in the literature. Kriwanek et al reported significant results in their experience with the use of stents for treatment of leaks after bariatric surgery.[2,5,6] The short-term results are promising, with a primary closure rate of 84% and immediate resumption of oral feeding after stenting.[2,3] Esophageal stent placement (endoluminal technique) is an effective and new strategy for the treatment of upper gastrointestinal enteric fistulas and may be performed safely to treat complications after bariatric surgery.

Figure 3. *Upper gastrointestinal series in the first postoperative day.*

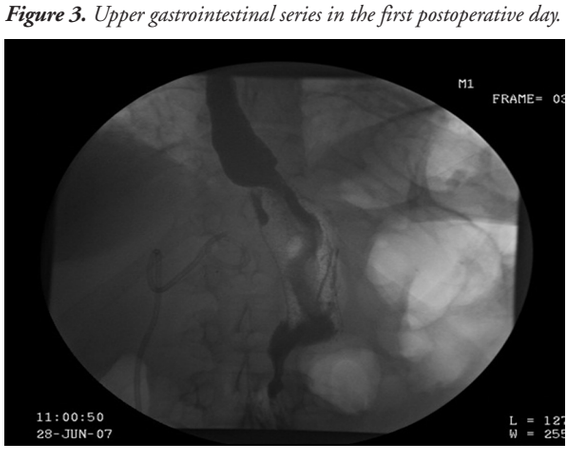

References

1. Strain GW, Gagner M, Inabnet WB, Hsieh J, Heacock L, Christos P. Comparison of effects of gastric bypass and biliopancreatic diversion with duodenal switch on weight loss and body composition 1-2 years after surgery. Surg Obes Relat Dis 2007;3:31-36.
2. Kowalski C, Kastuar S, Mehta V, Brolin RE. Endoscopic injection of fibrin sealant in repair of gastrojejunostomy leak after laparoscopic Roux-en Y gastric bypass. Surg Obes Relat Dis 2007;3:438-442.
3. Eisendrath P, Cremer M, Himpens J, Cadière GB, Le Moine O, Devière J. Endotherapy including temporary stenting of fistulas of the upper gastrointestinal tract after laparoscopic bariatric surgery. Endoscopy 2007;39:625-630.
4. Fukumoto R, Orlina J, McGinty J, Teixeira MD. Use of polyflex stents in treatment of acute esophageal and gastric leaks after bariatric surgery. Surg Obes Relat Dis 2007;3: 68-72.
5. Kriwanek S, Ott N, Ali-Abdullah S, Pulgram T, Tscherney R, Reiter M, Roka R. Treatment of gastro-jejunal leakage and fistulization after gastric bypass with coated self-expanding stents. Obes Surg 2006;16:1669-1674.
6. Nguyen NT, Longoria M, Welbourne S, Sabio A, Wilson SE. Glycolide copolymer staple-line reinforcement reduces staple site bleeding during laparoscopic gastric bypass. A prospective randomized trial. Arch Surg 2005;140:773-778.