Cell block technique and cytological smears for the differential diagnosis of pancreatic neoplasms after endosonography-guided fine-needle aspiration

José Celso Ardengh, César Vivian Lopes, Luiz Felipe Pereira de Lima, Filadélfio Venco, Giulio Cesare Santo, María Dirlei Begnami, José Luiz Pimenta Módena

Work performed in the Echoendoscopy and Pathology Units from 9 de Julho Hospital and Ribeirão Preto Medical School - USP, São Paulo. Brazil.

Acta Gastroenterol Latinoam 2008;38:246-251

Summary

Cytological smear is widely employed to analyse specimens obtained from endosonography-guided fine-needle aspiration (EUS-FNA), but false-negative or inconclusive results may occur. A better diagnostic yield can be obtained from processing cell blocks. We compared the effectiveness of the cell block technique and cytological smear in the diagnosis of pancreatic neoplasms. From January 1997 to December 2006, 611 patients with pancreatic tumors were evaluated by EUS-FNA. Surgery was performed in 356 cases, and the other 255 patients were followed clinically for an average of 12.8 months. In total, 282 (46.2%) patients were evaluated with cytological smears, and 329 (53.8%) were evaluated using only cell blocks. Malignant disease was detected in 352 (57.6%) cases, in which adenocarcinoma accounted for 236 (67%) cases. A benign disease was found in the other 259 cases, including 35.1% focal chronic pancreatitis and 32.4% pseudocysts. Aspiration samples were satisfactory in 595 (97.4%) patients after an average of 2.2 (1-4) passes of the needle. Regardless of the cytopathological examination technique, EUS-FNA confirmed malignancy in 269 of 352 (76.4%) cases, and a benign disease in 257 of 259 (99.2%) cases. For patients who received surgery with histologically confirmed lesions, the sensitivity, specificity, positive and negative predictive values, and accuracy of the smears versus cell blocks in diagnosing pancreatic tumors were 61% versus 85.2% (P<0.001), 100% versus 93.1%, 100% versus 98.4%, 36% versus 55.1% (P=0.046) and 68% versus 86.5% (P<0.001), respectively. The cell block technique demonstrated a higher sensitivity, negative predictive value and accuracy than cytological smears.

Key words: *cell block, cytological smear, diagnostic techniques, endoscopic ultrasound, fine needle aspiration, pancreatic neoplasm.*

Correspondence: *José Celso Ardengh*
Alameda dos Arapanés, 881 – cj 111, Moema – CEP 04524-001
Tel: 55 -11- 50557134 / Fax: 55- 11- 50558942
E-mail: jcelso@uol.com.br

Técnica de bloque de células y citológico de papanicolau para el diagnóstico diferencial de tumores de páncreas después de la EE-asociado con la punción aspirativa con aguja fina

Resumen

*El citológico de Papanicolau es ampliamente empleado para analizar los especímenes del ultrasonido endoscópico asociado con la punción aspirativa con aguja fina (UE-PAAF), aunque se pueden encontrar falsos negativos o no concluyentes resultados. Un mejor rendimiento diagnóstico se puede obtener del procesamiento de bloques de células (**cell block**). El objetivo fue analizar los resultados de la técnica de bloques de células y el citológico de Papanicolau en el diagnóstico de los tumores pancreáticos. Desde enero de 1997 a diciembre de 2006, 611 pacientes con tumores de páncreas fueron sometidos a lo UE-PAAF. La cirugía se realizó en 356 casos y 255 pacientes recibieron seguimiento clínico por un promedio de 12,8 meses. En total, 282 (46,2%) pacientes fueron remitidos al frotis, y 329 (53,8%) utilizan solamente los bloques de células. Una enfermedad maligna se detectó en 352 (57,6%) en quienes un adenocarcinoma aconteció en 236 (67%) casos. Una enfermedad benigna se encontró en 259 casos, pancreatitis crónica focal pseudoquistes y contabilidad, respectivamente, de 35,1% y 32,4% de*

estos casos. Aspiración de las muestras fueron satisfactorias en 595 (97,4%) pacientes después de una media de 2,2 (1-4) pases de la aguja. Independientemente de la técnica citopatológica, UE-PAAF confirmó una malignidad en 269 de 352 (76,4%) casos, y una enfermedad benigna en 257 de 259 (99,2%) casos. Para los pacientes sometidos a cirugía con lesiones histológicamente confirmado la sensibilidad, especificidad, valores predictivos positivo y negativo, y la exactitud del citológico de Papanicolau y bloque de células para el diagnóstico de tumores de páncreas fueron, respectivamente, 61% x 85,2% (P <0,001), 100 % X 93,1%, 100% x 98,4%, 36% x 55,1% (P = 0.046) y el 68% x 86,5% (P <0,001).El bloque de células es una técnica que ha demostrado una mejor sensibilidad, valor predictivo negativo y exactitud de frotis citológico para el diagnóstico de los tumores pancreáticos.

Palabras claves: *bloque de células, citológico de Papanicolau, las técnicas de diagnóstico, ultrasonido endoscópico, aspiración con aguja fina, neoplasia de páncreas.*

Since EUS-guided fine needle aspiration (EUS-FNA) was first used to diagnose pancreatic carcinoma in the early 1990's,[1] the procedure has become the most accurate modality for the characterizing pancreatic lesions, locoregional staging, and sampling pancreatic tumor tissues.[2-4] The traditional cytological smear has been widely used to analyse the specimens collected from EUS-FNA, which is easy to prepare, inexpensive, and fast and produces no cellular trauma.[5-7] However, smears are sometimes unsatisfactory for evaluation because of haemorrhage and scarce cellularity even after multiple passes of the needle, and false-negative or inconclusive results may occur.[8,9] In fact, nearly 30% of patients with a negative biopsy may have a malignancy.[4]To overcome these drawbacks, processing cell blocks can provide diagnostic information that is more useful for diagnosis. Using this method, small tissue specimens are processed for routine histological slides, guaranteeing that the cells aspirated from pancreatic tumors are used to a maximum extent. In addition to improving the yield of diagnostic cytology, molecular techniques such as immunocytochemistry can be used to detect non-morphological markers to assist the conventional cytomorphology examination when a sufficient number of slides are available.[10-13]

We conducted this study to evaluate the accuracy of cytological smear and cell block technique in the differential diagnosis of pancreatic neoplasms from aspirated specimens obtained by EUS-FNA.

Material and methods

From January 1997 to December 2006, 1043 patients with pancreatic tumors were referred to our Service in the 9 de Julho Hospital and Ribeirão Preto Medical School – USP for EUS-FNA, and 611 (58.6%) patients were available for the retrospective review. The final diagnosis was based on histology obtained from either surgical resection (n = 356) or clinical follow-up with a mean duration of 12.8 (range: 2 to 32) months (n = 255). The EUS-FNA procedure was carried out by an experienced endosonographer (JCA) using a linear echoendoscope FG-38UX (Pentax Precision Instruments, Inc., Orangeburg, NY) with an Hitachi 405 EUB ultrasound platform. EUS-FNA was performed with a 22-gauge, 8-cm shotgun aspiration needle (NA-11J-KB, Olympus Optical Co., Tokyo, Japan) with the patient under conscious sedation with propofol and cardiorespiratory monitoring. Patients were kept lying on their left side and an overnight fast before the procedure. Antibiotic prophylaxis was given during the procedure. The passage of the needle was transduodenal for lesions in the head/uncinate process of the pancreas and transgastric through the lesser sac for lesions in the body and tail of the pancreas.

The aspirated samples from the first 282 (46.2%) patients were evaluated with the traditional cytological smears. After January 2000, the cell block technique was adopted in our routine practice and used for the rest of the patients (53.8%). Although cytopathologist was not present during every procedure, the specimens were considered satisfactory in the presence of non-hemorrhagic small tissue filaments or tissue core samples.

Cytopathological assessment

All cytological samples were interpreted by one of two experienced cytopathologists (FV and GCS). Smears were prepared and stained by the usual protocol. Once aspirated, the sample was expelled onto slides, and two smears were made, followed by fixation in 10% phosphate buffered formalin. The specimens were considered inadequate if acellular material was present. Specimens for cell blocking were obtained from the hub of the FNA biopsy needle by flushing the needle with 2 ml sterile saline into a 10% buffered neutral formalin solution. Shortly afterwards, the stylet was reintroduced into the needle in order to ex-

tract residual content. The sample obtained was centrifuged for 5 min at 2000 rpm. The supernatant was discarded and the cells were transferred into a 1.5 ml Eppendorf tube, then resuspended in 1 ml 2% liquid agarose as an intermediate embedding medium. The reaction tube was again centrifuged for 1 min at 1000 rpm to concentrate the cells in the agar. Once solidified, the agar cone with the cells in the top layer was taken out of the reaction tube, wrapped in filter paper, and embedded in paraffin. At this point, the sample could be handled as a routine tissue block. Thin 3mm-sections from paraffin-embedded cell block were cut, mounted on glass slides, and stained with haematoxylin and eosin (Figure 1). When each slide was examined, the cellularity, presence of loosely cohesive aggregates or single tumor cells, quality and quantity of cytoplasm, nuclear pleomorphism, chromatin patterns, nucleus-to-cytoplasm ratio, and necrosis were systematically analysed. If the HE stain did not provide a clear diagnosis, especially when neuroendocrine tumors such as lymphoma and sarcoma were suspected, immunocytochemical stains were carried out using the avidin–biotin peroxidase method to confirm the diagnosis.

Figure 1. *Thin sections from paraffin-embedded cell blocks stained with haematoxylin and eosin (**a**. Low-grade IPMT. Columnar cells arranged in cohesive folds with mucinous hypertrophy in the apical. Extracellular background with moderate amount of mucin (arrows). Original magnification: 200x; **b**. PanIN. Columnar to cuboidal cells with bland mucin apical without cytological or architectural atypia. Original magnification: 200x; **c**. Serous cystadenoma. Cyst linead by a single layer of cuboidal or flattened epithelial cells. The uniform nuclei are round to oval in shape. There is no mucin intra or extracellular. Original magnification: 400x).*

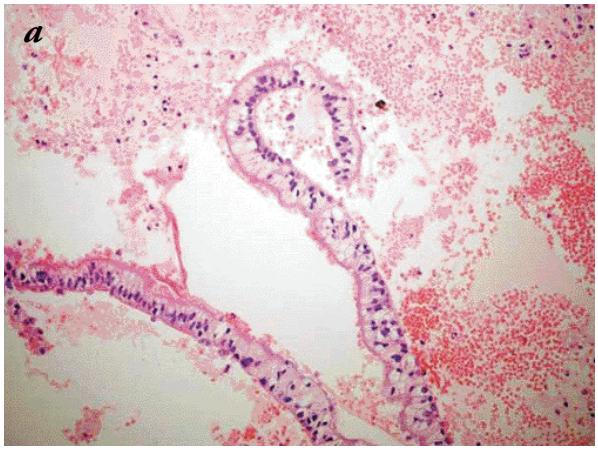

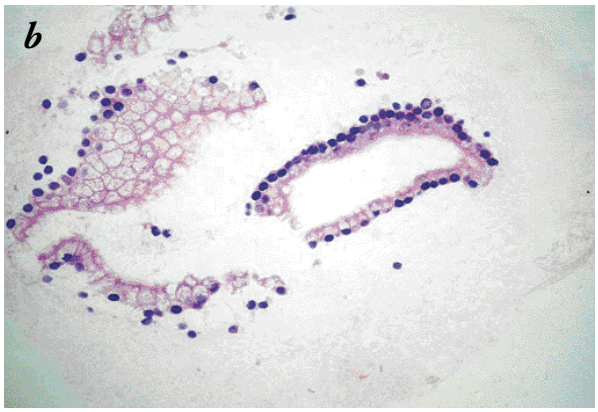

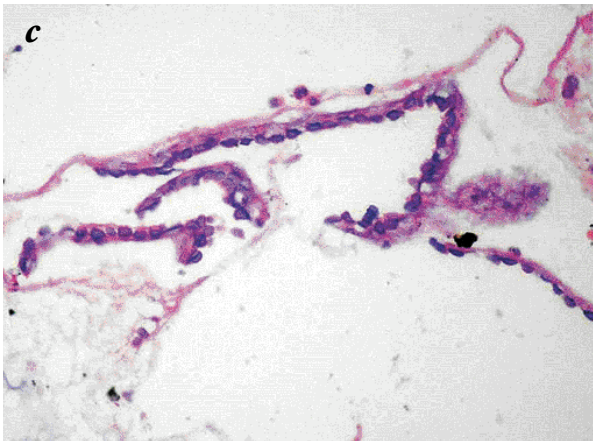

Statistical analysis

Categorical data were analysed by chi-square test using the Yates correction and Fischer exact test. Sensitivity, specificity, positive and negative predictive values, and accuracy were calculated with a 2 x 2 table. The significance level was set at 5% for all statistical comparisons between the cell block technique and cytological smears.

This study was approved by the Research Ethics Boards of 9 de Julho Hospital and Ribeirão Preto Medical School – USP. Written informed consent was obtained from every patient who underwent the procedure and had their tissue samples analysed.

Results

The mean age of the 611 patients included in the study was 57.8 (range: 11-89) years. Three hundred fourteen patients (51.4%) were female and 297 (48.6%) were male.

The main reasons for the referrals to the EUS-FNA examination for pancreatic lesions were sus-

pected solid malignant neoplasia (44.2%), cystic collections (28.3%), and the need for differential diagnosis between pancreatic cancer and focal chronic pancreatitis (11.6%). Other indications are listed in Figure 2.

Figure 2. *Indications for Pancreatic EUS-FNA (n=611).*

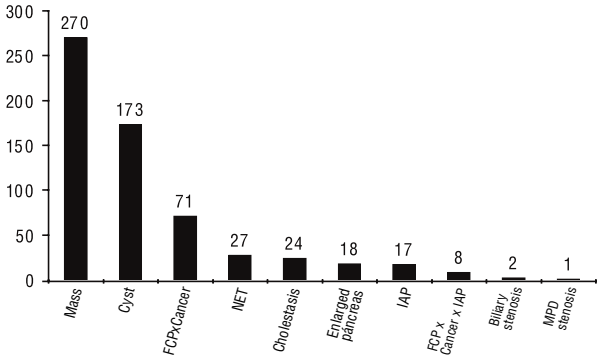

FCP: focal chronic pancreatitis; NET: neuroendocrine tumor; IAP: idiopatic acute pancreatitis; MPD: main pancreatic duct.

In 444 (66.1%) patients, the tumors were located in the head, 159 (26%) in the body, 42 (6.9%) in the tail, and 6 (1%) in the neck of the pancreas. The passage was transduodenal for 410 (67%) tumors and transgastric for 201 (33%) cases. The mean size of the tumors was 3.4 (range:0.4-14.4) cm, and lesions less than 3 cm accounted for 43% of the cases.

The EUS diagnosed 405 (66.3%) solid tumors, 189 (30.9%) cystic collections, and 17 (2.8%) mixed-pattern lesions. Malignancy was detected in 352 (57.6%) cases. Adenocarcinoma was diagnosed in 236 (38.6%) cases. The diagnoses of the remaining cases are depicted in the Table 1. Aspiration samples were successfully collected in 595 (97.4%) patients after an average of 2.2 (range: 1–4) passes. The remaining 16 cases werediagnosed only after surgical resection.

The cytological diagnoses of malignancy obtained by EUS-FNA, either by smears or cell blocks, were consistent with the diagnoses from surgery or clinical follow-up in 269 of the 352 (76.4%) cases. In addition, the cytopathology examination correctly classified 257 of the 259 (99.2%) benign cases.

The overall sensitivity, specificity, positive and negative predictive values, and diagnostic accuracy of all the EUS-FNA evaluations for the diagnosis of pancreatic tumors were 78.4%, 99.2%, 99.3%, 77.2%, and 87.2%, respectively. For patients undergoing surgery with histologically confirmed lesions, the sensitivity, specificity, positive and negative predictive values, and diagnostic accuracy for smears versus cell blocks were, respectively, 61% versus 85.2%, 100% versus 93.1%, 100% versus 98.4%, 36% versus 55.1%, and 68% versus 86.5% (Table 2).

Table 1. *Diagnoses of Pancreatic Lesions Obtained by Surgery or Clinical Follow-Up.*

TUMOR	TYPE	N
Solid (n=405)	Adenocarcinoma	233
	Focal Chronic Pancreatitis	87
	Neuroendocrine tumor	46
	Metastasis	13
	Lymphnode	9
	Splenosis	4
	Lymphoma	4
	Autoimmune pancreatitis	4
	Adenoma	2
	Sarcoma	2
	Blastomycosis	1
Cystic (n=189)	Pseudocyst	84
	Serous cystadenoma	42
	Mucinous cystadenoma	18
	IPMT	18
	Abscess	12
	PanIN	8
	Chronic Pancreatitis	4
	Tuberculosis	2
	Neuroendocrine tumor	1
Mixed (n=17)	Cystadenocarcinoma	8
	Adenocarcinoma	3
	Solid Pseudo Papillary Tumor	3
	IPMT	1
	Metastasis	1
	Neuroendocrine tumor	1
TOTAL		611

IPMT: Intraductal Papillary Mucinous Tumor; PanIN: pancreatic intraepithelial neoplasia.

Table 2. *Sensitivity, Specificity, Positive and Negative Predictive Values, and Accuracy of Cytological Smear and Cell Block Technique for the Diagnosis of Pancreatic Tumors*.*

	Cytological Smear (n=178)	Cell Block (n=178)	P
Sensitivity	61% (53-68.9)	85.2% (79.5-90.9)	< 0.001 [a]
Specificity	100% (100–100)	93.1% (83.9–100)	0.222 [b]
PPV	100% (100–100)	98.4% (96.3–100)	0.647 [b]
NPV	36% (26-45.9)	55.1% (41.2-69)	0.046 [b]
Accuracy	68% (61.1-74.8)	86.5% (81.5–91.5)	< 0.001 [a]

* Only for patients undergoing surgery with histologically confirmed lesions.
[a] McNemar test; [b] Chi-square
PPV: Positive Predictive Value; NPV: Negative Predictive Value
95% confidence intervals (CIs) are presented in parentheses.

Discussion

There is currently no consensus on the best way to process aspirated samples from pancreatic cancer, either for the ideal cytopathological technique or proper sample handling for each technique. The accuracy of FNA depends on the adequacy of the tissue aspiration. In some studies, up to 20% of samples were inadequate.[14,15] In addition, the interpretation of cytological smears may be less accurate at institutions where few EUS-FNA procedures are performed.[16,17] Indeed, the quality of the specimens and the proper handling of the aspirated samples are crucial to the success of cytological examination8. Combining conventional smears and cell blocks can increase the information obtained from EUS-FNA and provide more accurate and clinically useful findings.[3,17]

In our study, the cell block technique showed a higher sensitivity and diagnostic accuracy for pancreatic neoplasms than traditional cytological smears. Moreover, although the two methods were similar in specificity and positive predictive values, the cell block technique had a higher negative predictive value, indicating a better diagnostic yield. A group of experts have suggested that a higher negative predictive value is desirable to prevent unnecessary pancreatic surgeries.[4]

The accuracy and effectiveness of cell blocks in diagnosing pancreatic neoplasms has not been addressed before. In the first large study of this technique used in pancreatic specimens obtained by EUS-FNA, Mitsuhashi et al.[5] found that cell blocks included diagnostic material in 91 of 114 (80%) positive or suspicious cases. In addition, the cell block method was exclusively diagnostic in 20% of the cases in cases where the corresponding smears were non-diagnostic. Brown et al.[18] similarly found that cell blocks of aspirates from different organs increased the diagnostic accuracy in 14% of the cases. In the Brown study,[18] neuroendocrine tumors such as lymphomas and plasmacytomas were confirmed based on the immunocytochemical stains performed on cell block sections. Overall, cytological smears in combination with cell blocks was sensitive (94.6%), specific (100%), and accurate (95.6%) in the differential diagnosis of pancreatic neoplasms, which was similar to our study findings.

In our study, we did not calculate the costs of routine use of cell blocks in cytological procedure for FNA specimens. Nevertheless, it is important to point out that some authors believe that cell blocks are not only more time-consuming than conventional smears but also not cost-effective to be used routinely in addition to smears for detecting malignancy;[6,19,20] however, it could be cost-effective when the cytological smear is nondiagnostic. Liu et al.[6] compared the diagnostic accuracy of smears and cell blocks in 483 cases. Cell block contributed additional information beyond what had been obtained from smears in 12% of cases, and in 44% of cases in which the smears were nondiagnostic.

Despite the added cost, the cell block technique is gathering more interest, and new approaches of implementing the procedure in the current cytology practice have been described that makes it easier, faster, and more cost-effective.[11,12,21] To date, few studies and case reports have been published to describe the applicability of this technique in gastrointestinal neoplasms examined through EUS-FNA. Ceyhan et al.[7] evaluated the diagnostic accuracy of smears and cell blocks in 167 patients with liver tumors. The diagnostic accuracy of cytological smear, cell block, and the combination of both techniques were 94%, 87%, and 94.5%, respectively. In a study by Chang et al.,[22] the final diagnosis of 2 out 9 cases previously interpreted as suspicious for neuroendocrine tumors was confirmed by the immunocytochemical stains of cell blocks with positive cells for neuroendocrine markers. DeWitt et al.[23] reported the diagnosis of malignant melanoma metastatic to the pancreas only after the cytopathological assessment of the cell blocks.

To obtain biopsies of higher quality and more accurate diagnosis, some endoscopic devices such as the 19–gauge trucut and aspiration needles have been developed to improve specimen extractions. However, studies have shown that these needles did not improve the success of tissue sampling from pancreatic tumors or diagnostic sensitivity compared with the standard 22-gauge aspiration needles.[24-27]

Other than the cell blocks, which prevents cell loss in paucicellular samples, liquid-based cytology is another method that can increase the cellularity of the specimen and improve the diagnostic yield and accuracy of FNA. It provides a monolayered cell slide with a cleaner background and facilitates cytological evaluation and complementary studies.[2,28,29] Its application to pancreatic FNA specimens has been limited, however, because it is somewhat more complex, time-consuming, and more expensive and is not widely available in most cytopathology laboratories.

By processing small tissue specimens for routine histological assessment, the cell block technique can

maximally use the tissue sample aspirated from pancreatic tumors. It is also better for obtaining specimens for research and teaching than conventional smears. Regardless of the technique for cytopathological assessment, that the correct preparation of the specimens is the most important step in reducing the number of false-negative results and allowing for the correct and adequate use of diagnostic test.

Future research should be performed to evaluate both cytological techniques for specific pancreatic tumors. Defining the diagnostic yield for each cytological procedure will determine the place of the cell block technique in cytopathological practice for the assessment of pancreatic neoplasms.

References

1. Chang KJ, Albers CG, Erickson RA, Butler JA, Wuerker RB, Lin F. Endoscopic ultrasound-guided fine needle aspiration of pancreatic carcinoma. Am J Gastroenterol 1994; 89:263-266.
2. Weynand B, Deprez P. Endoscopic ultrasound guided fine needle aspiration in biliary and pancreatic diseases: pitfalls and performances. Acta Gastroenterol Belg 2004;67:294-300.
3. Chang KJ. State of the art lecture: endoscopic ultrasound (EUS) and FNA in pancreatico-biliary tumors. Endoscopy 2006;38 (Suppl 1):S56-S60.
4. Arcidiacono PG, Bhutani MS, Giovannini M. EURO-EUS 2003: Pancreatic Tumor - Impact of Endoscopic Ultrasonography on Diagnosis, Staging and Treatment. Cancer Biol Ther 2004;3:477-481.
5. Mitsuhashi T, Ghafari S, Chang CY, Gu M. Endoscopic ultrasound-guided fine needle aspiration of the pancreas: cytomorphological evaluation with emphasis on adequacy assessment, diagnostic criteria and contamination from the gastrointestinal tract. Cytopathology 2006;17:34-41.
6. Liu K, Dodge R, Glasgow BJ, Layfield LJ. Fine-needle aspiration: comparison of smear, cytospin, and cell block preparations in diagnostic and cost effectiveness. Diagn Cytopathol 1998;19:70-74.
7. Ceyhan K, Kupana SA, Bektas M, Coban S, Tuzun A, Cinar K, et al. The diagnostic value of on-site cytopathological evaluation and cell block preparation in fine-needle aspiration cytology of liver masses. Cytopathology 2006;17:267-274.
8. Fabre M, Labadie M. Rapid staining and guided fine needle aspiration for deep masses: a focus. Clin Exp Pathol 1999;47:297-302.
9. Bardales RH, Stelow EB, Mallery S, Lai R, Stanley MW. Review of endoscopic ultrasound-guided fine-needle aspiration cytology. Diagn Cytopathol 2006;34:140-175.
10. Domagala WM, Markiewski M, Tuziak T, Kram A, Weber K, Osborn M. Immunocytochemistry on fine needle aspirates in paraffin miniblocks. Acta Cytol 1990;34:291–296.
11. Nathan NA, Narayan E, Smith MM, Horn MJ. Cell block cytology. Improved preparation and its efficacy in diagnostic cytology. Am J Clin Pathol 2000;114:599-606.
12. Mansy SS, Abbas MA, Yehia HA, Abdelrazik SM, Ghanem LY, Amin TM. Value of the innovated technique agarose cell block in improving the sensitivity of urine cytology in cases of bladder carcinoma. Ultrastruct Pathol 2006;30: 379-385.
13. Karnauchow PN, Bouin RE. Cell-block technique for fine needle aspiration biopsy. J Clin Pathol 1982;35:668.
14. David O, Green L, Reddy V, Kluskens L, Bitterman P, Attal H, et al. Pancreatic masses: a multi-institutional study of 364 fine-needle aspiration biopsies with histopathologic correlation. Diagn Cytopathol 1998;19:423-427.
15. Eloubeidi MA, Chen VK, Eltoum IA Jhala D, Chhieng DC, Jhala N, et al. Endoscopic ultrasound-guided fine needle aspiration biopsy of patients with suspected pancreatic cancer: diagnostic accuracy and acute and 30-day complications. Am J Gastroenterol 2003;98:2663-2668.
16. Harewood GC, Wiersema LM, Halling AC, Keeney GL, Salamao DR, Wiersema MJ. Influence of EUS training and pathology interpretation on accuracy of EUS-guided fine needle aspiration of pancreatic masses. Gastrointest Endosc 2002;55:669-673.
17. Alsibai KD, Denis B, Bottlaender J, Kleinclaus I, Straub P, Fabre M. Impact of cytopathologist expert on diagnosis and treatment of pancreatic lesions in current clinical practice. A series of 106 endoscopic ultrasound-guided fine needle aspirations. Cytopathology 2006;17:18-26.
18. Brown KT, Fulbright RK, Avitabile AM, Bashist B. Cytologic analysis in FNA biopsy-Smears v/s cell block. Am J Roentgenol 1993;161:629-631.
19. Zito FA, Gadaleta CD, Salvatore C, Filotico R, Labriola A, Marzullo A, et al. A modified cell block technique for fine needle aspiration cytology. Acta Cytol 1995;39:93-99.
20. Jonasson JG, Ducatman BS, Wang HH. The cell block for body cavity fluids: do the results justify the cost? Mod Pathol 1990;3:667-670.
21. Musso C, Silva-Santos MC, Pereira FE. Cotton block method: one-step method of cell block preparation after fine needle aspiration. Acta Cytol 2005;49:22-26.
22. Chang F, Vu C, Chandra A, Meenan J, Herbert A. Endoscopic ultrasound-guided fine needle aspiration cytology of pancreatic neuroendocrine tumours: cytomorphological and immunocytochemical evaluation. Cytopathology 2006;17:10-17.
23. DeWitt JM, Chappo J, Sherman S. Endoscopic ultrasound-guided fine-needle aspiration of melanoma metastatic to the pancreas: report of two cases and review. Endoscopy 2003;35:219-222.
24. Itoi T, Itokawa F, Sofuni A, Nakamura K, Tsuchida A, Yamao K, et al. Puncture of solid pancreatic tumors guided by endoscopic ultrasonography: a pilot study series comparing Trucut and 19-gauge and 22-gauge aspiration needles. Endoscopy 2005;37:362-366.
25. Ihse I, Axelson J, Dawiskiba S, Hansson L. Pancreatic biopsy: why? When? How? World J Surg 1999;23:896-900.
26. Larghi A, Verna EC, Stavropoulos SN, Rotterdam H, Lightdale CJ, Stevens PD. EUS-guided trucut needle biopsies in patients with solid pancreatic masses: a prospective study. Gastrointest Endosc 2004; 59: 185-190.
27. Wittmann J, Kocjan G, Sgouros SN, Deheragoda M, Pereira SP. Endoscopic ultrasound-guided tissue sampling by combined fine needle aspiration and trucut needle biopsy: a prospective study. Cytopathology 2006;17:27-33.
28. Fabre M, Monges G. Cytopathologie pancreatique par recueil des cellules en milieu liquid. In: Fabre M, Cochand-Priollet B, eds. Cytopathologie non gynecologique en milieu liquide. Paris: Elsevier 2003.103-115.
29. de Luna R, Eloubeidi MA, Sheffield MV, Eltoum I, Jhala N, Jhala D, et al. Comparison of ThinPrep and conventional preparations in pancreatic fine-needle aspiration biopsy. Diagn Cytopathol 2004;30:71-76.